ARTICLE IN PRESS

ELSEVIER
SAUNDERS

VETERINARY
CLINICS
Exotic Animal Practice

Vet Clin Exot Anim ■ (2008) ■–■

Hematologic Disorders of Fish

Tonya M. Clauss, DVM, MS[a,*],
Alistair D.M. Dove, PhD[a], Jill E. Arnold, MS, MT[b] [Q2]

[a]*Veterinary Services and Conservation Medicine, Georgia Aquarium, 225 Baker Street, Atlanta, GA 30313, USA*
[b]*National Aquarium in Baltimore, Pier 3, 501 East Pratt Street, Baltimore, MD 21202, USA* [Q3][Q4]

Most fish health research and medicine traditionally has focused on aquaculture and food fish species. As society recognizes the need for conserving and protecting its natural resources, public aquarium facilities, commercial ornamental fish producers, collectors, and hobbyists are following the lead of the aquaculture industry by improving fish health practices for popular display fish. The growth of domestic animal medicine as a discipline over the past few decades also has had an impact on fish medicine. Pets, including fish, often are believed members of the family and, as a result, more private practitioners are being consulted about pet fish health. Hematologic data not always have been used in evaluating fish health because of the difficulty of obtaining samples, the challenges involved in evaluating hemograms, and the lack of meaningful reference intervals to aid in interpretation. Hematologic evaluation can be useful in monitoring the health status of fish, as long as interpretation accounts for intrinsic and extrinsic factors that can influence the appearance of cells and the quantitative values obtained. Care must be taken when comparing data as many published reference ranges do not account for differences attributed to factors, such as age, gender, water quality, and season. Even the capture, handling, and anesthetics involved in obtaining blood samples from fish can have profound affects on the hemogram [1].

Hematologic disorders are marked by aberrations in structure or function of the blood cells or the mechanisms of coagulation. Although many other diseases may be reflected by the blood and its constituents, the abnormalities of erythrocytes, leukocytes, thrombocytes, and clotting factors are considered primary blood disorders. Diseases of fish may result in anemia, leukopenia, leukocytosis, thrombocytopenia, and other blood cell abnormalities.

* Corresponding author.
E-mail address: tclauss@georgiaaquarium.org (T.M. Clauss).

1094-9194/08/$ - see front matter © 2008 Elsevier Inc. All rights reserved.
doi:10.1016/j.cvex.2008.03.007 *vetexotic.theclinics.com*

UNCORRECTED PROOF

ARTICLE IN PRESS

This article summarizes some of the salient features of hematologic analysis in teleosts (bony fishes) and elasmobranchs (sharks and rays) and outlines the ways in which the major types of diseases can present themselves in a fish hemogram. Blood sample collection and handling techniques for both classes of fishes are described in the literature [2–5] and are not discussed further in this review.

Normal erythrocytes

Erythrocytes of teleost fishes have similar appearance and ultrastructure to those of other nonmammalian vertebrates. The cells are oval to elliptic in shape with abundant pale, eosinophilic cytoplasm and centrally positioned oval to elliptic nuclei, which is moderately to deeply basophilic (Fig. 1). Elasmobranch erythrocytes are similar in appearance to those of teleosts but considerably larger (Fig. 2). A small amount of erythropoiesis occurs in the peripheral blood of both classes of fish, so it is common to find a small percentage of immature erythrocytes when examining a hemogram from a normal fish [6,7]. Moderate anisocytosis and polychromasia also is normal in many species of teleosts and elasmobranchs. Immature erythrocytes tend to be more rounded than oval with a blue-tinted cytoplasm and larger, more heterochromatic nucleus, thus a higher nucleus to cytoplasm ratio. Erythrocyte morphology, interspecific variation, and variations noted in response to intrinsic and extrinsic variables are summarized in detail in existing literature [4,5].

Techniques for laboratory evaluation of erythrocytes also are well described [4,5,8,9]. Examining morphology, determining the packed cell volume (PCV), and obtaining total erythrocyte counts and red blood cell indices, such as mean cell volume, mean corpuscular hemoglobin concentration, and mean corpuscular hemoglobin, all can be useful in diagnosing disease. PCV varies within and between species and seems to correlate with the normal activity level of the fish. For example, actively swimming species, such as tuna and other pelagic species, tend to have much higher PCVs than would a sedentary bottom dweller, such as a flatfish. Elasmobranchs have lower concentrations of larger cells and usually have lower PCVs. As with other hematologic parameters, PCV values may vary with age, gender, water quality, photoperiod, diet, and season [10–17]. In the absence of established reference ranges, an accepted PCV range for fish is 20% to 45% [17].

Normal leukocytes

Leukocytes of fishes are variable between species (see Figs. 1 and 2), such that initially it can be hard to identify some cell types. The main leukocytes can be identified using a comparative approach and process of elimination on a typical blood smear processed with a three-step Romanowsky-type

UNCORRECTED PROOF

ARTICLE IN PRESS

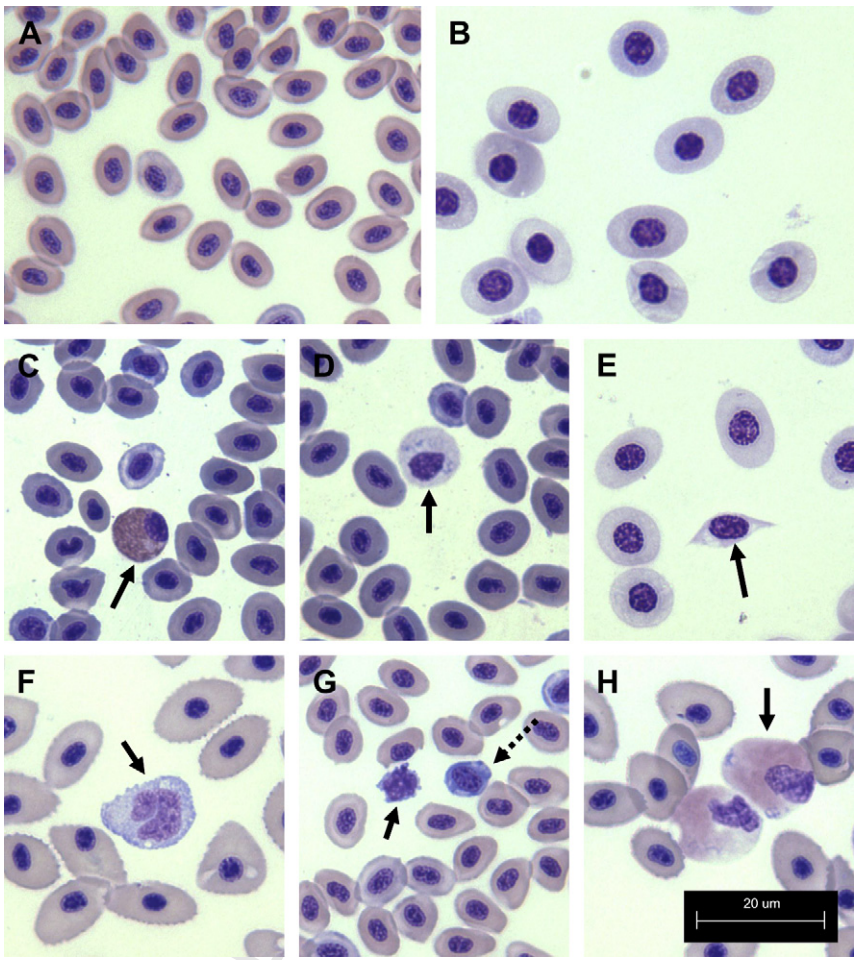

Fig. 1. Normal teleost blood cell morphology. (*A*) Mature erythrocyte morphology of golden trevally, *Gnathanodon speciosus*. (*B*) Mature erythrocyte morphology of ocean sunfish *Mola mola*, showing comparatively larger cells. (*C*) Eosiniophil of a goatfish *Upeneus* sp showing marginal nucleus and large cigar-shaped eosinophilic granules. (*D*) Neutrophil of goatfish showing pale cytoplasm with sparse granulation (some basophily in this case) and eccentric unsegmented nucleus. (*E*) Thrombocyte of ocean sunfish showing spindle shape typical of many teleost thrombocytes. (*F*) Monocyte of the arowana *Osteoglossum bichirrosum* showing typical indented nucleus and abundant vacuolated basophillic cytoplasm. (*G*) Mature lymphocyte (*solid arrow*) and immature erythrocyte (*dashed arrow*) of golden trevally. Note that the immature erythrocyte nucleus is essentially similar to that of mature erythrocytes and that, despite the similar basophilic nature, there is comparatively more cytoplasm in the immature erythrocyte. (*H*) Heterophils of the arowana showing pale basophillic cytoplasm and abundant tiny eosinophillic granules. These cells may fill the same roles as the neutrophils in (*D*) (see text for further discussion).

print & web 4C/FPO

UNCORRECTED PROOF

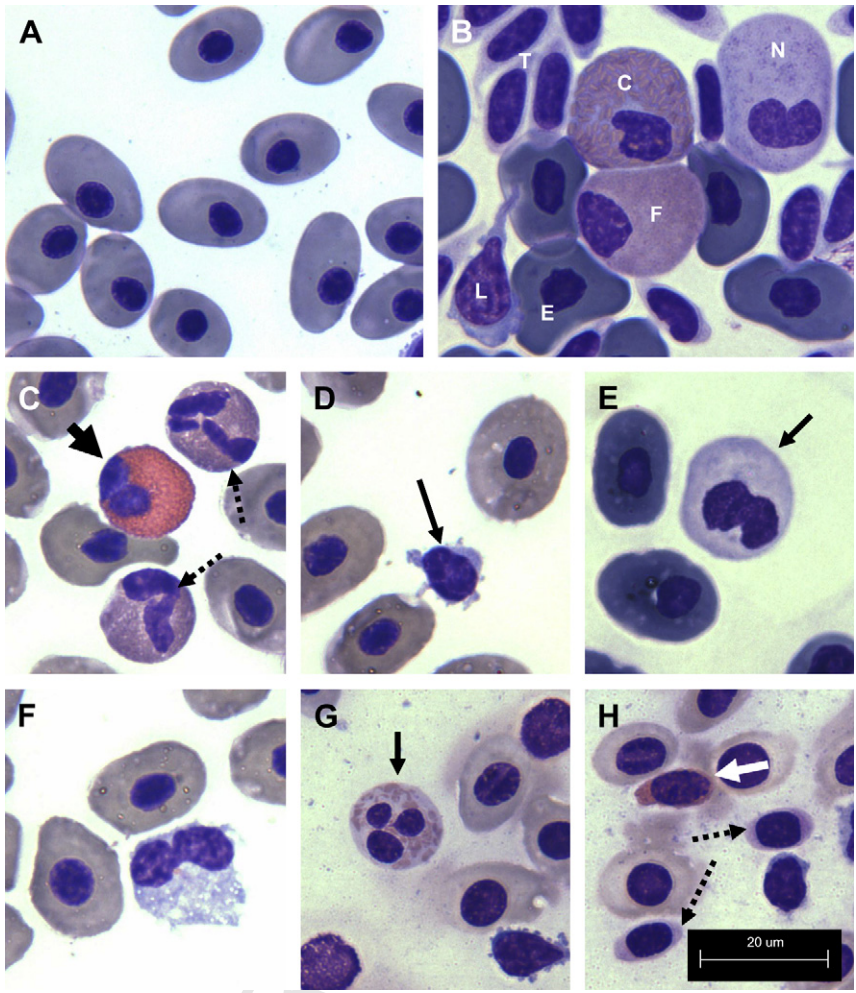

Fig. 2. Normal elasmobranch blood cell morphology. (*A*) Mature erythrocyte morphology of bonnet head shark, *Sphyrna tiburo*, note throughout the plate that erythrocytes are much larger than those of teleosts shown in Fig. 1. (*B*) Buffy coat smear from the whale shark, *Rhinchodon typus,* showing erythrocytes (E), a lymphocyte (L), heterophil (F), eosinophil (C), neutrophil (N) and thromboytes (T). (*C*) Eosinophil or CEG (*solid arrow*) and two heterophils or FEG (*dashed arrows*) in the blood of a southern ray, *Dasyatis americana*. The granules of the CEG have vivid eosinophilic properties and are larger and cigar shaped. (*D*) Lymphocyte (*arrow*) of southern ray showing sparse basophilic cytoplasm, dense nucleus and blebbing of the plasma membrane. (*E*) Neutrophil of spotted wobbegong, *Orectolobus maculatus*. (*F*) Monocyte of the southern ray showing typical indented nucleus and abundant vacuolated basophillic cytoplasm. (*G*) CEG of the carcharhinid black tip shark *Carcharhinus melanopterus*. This cell type has larger granules similar to the eosniophil or CEG of other shark orders, but the tinctorial properties are more similar to the heterophil or FEG found in other orders. The same applies to carcharhinid FEGs, which display vivid eosinophilia, despite their smaller granules. The homologies of these two cell types with the CEG and FEG of other elasmobranch orders have not been established. (*H*) Thrombocytes in the blood of the black tip shark. Both granular (*white arrow*) and agranular (*dashed arrows*) thrombocytes occur in this species.

print & web 4C/FPO

ARTICLE IN PRESS

hematology stain. Evaluation of ultrastructure and thorough review of fish leukoctyes in the literature has alleviated some of the confusion and difficulty associated with hemogram evaluation. Teleost and elasmobranch leukocytes are discussed briefly. In-depth summaries of identification and laboratory evaluation can be found in the literature [2,4,5,8,9,18].

Lymphocytes are the most common and probably most variable leukocyte in most healthy teleosts and elasmobranchs. These are small cells with densely basophilic nuclei and, usually, a very small amount of distinctly blue cytoplasm; the nucleus-to-cytoplasm ratio is high. They sometimes are rounded but often irregular in shape and often with "blebs" or blister-like outpocketings of the outer membrane. Reactive lymphocytes are larger and plasma cells do occur and can appear 2 to 3 times larger than regular lymphocytes [9].

The most common granulocyte of teleosts is the neutrophil. These typically are rounded cells that have nuclei that may or may not be segmented and their cytoplasm varies from extremely pale to gray or slightly blue, depending on the species [19,20]. The nucleus-cytoplasm ratio is low and cells tend to be similar to or larger than erythrocytes, rarely if ever smaller. Granulation also varies from indistinct to obvious, with the granules themselves appearing anywhere from glassy to slightly eosinophilic or basophilic. Some cell populations with more prominent eosinophilic granules can resemble heterophils of birds and reptiles or the heterophil or fine eosinophilic granulocyte (FEG) of elasmobranchs. Campbell [4] and Campbell and Ellis [5], however, conclude that there are enough functional studies to show that these cells fill the neutrophil role in the teleost leukocyte panoply. Although immature neutrophils occur in the circulating blood of teleosts, they do not resemble the classic band cell of the mammalian leukogram. In typical neutrophils and heterophils, the nucleus may be segmented or nonsegmented in mature cells depending on species and, sometimes, within a species. Neutrophils also are found commonly in elasmobranch species. The nuclei can be lobed or round. The cytoplasm is colorless with no visible granulation [8,9]. [Q5]

True eosinophils are less common in teleosts whereas basophils are rare. The granules of eosinophils tend to be larger and more distinct than those of the neutrophil/heterophil series, round or rod-shaped, and prominently eosinophilic; they are not easily overlooked. Basophils, when they occur, contain granules that stain so darkly as to obscure the nucleus [4]. In contrast, elasmobranchs show abundant eosinophilic cells, generally falling into two morphologic types. Consistent in sharks and rays is a cell that closely resembles the avian heterophils, with elongated, rod-shaped granules that stain a reddish color in Romanowsky-type stains. Nomenclature varies in the literature; this article uses the terminology described by Hine and Wain [21,22] as FEG. The second cell type, termed coarse eosinophilic granulocyte (CEG), is of equal size, but the granules are round and usually less abundant in the cytoplasm. The staining properties vary with species; most shark and ray CEGs stain orange to bright orange whereas the carhcharinid

UNCORRECTED PROOF

ARTICLE IN PRESS

CEG granules stain pale pink. The nuclei can be lobed or round in the FEG and CEG cells. Basophils rarely, if ever, are present in shark species but commonly found in rays. Elasmobranch leukocyte function warrants further study.

Monocytes of teleosts and elasmobranchs are similar to those of other vertebrates; they probably are the largest cells in any differential, irregular in shape, with an eccentric, large, heterochromatic nucleus (often indented or kidney shaped) and abundant slightly basophilic cytoplasm replete with vacuoles and other membrane-bound organelles.

Abnormalities of erythrocytes and leukocytes

Hematologic abnormalities involving the erythrocytes of fish include polycythemia, anemia, abnormal morphology, and nuclear or cytoplasmic inclusions. Like other vertebrates, fish leukograms are affected by disease, inflammatory processes, stress, nutrition, and physiologic and environmental factors. During disease processes, the leukogram of teleosts can show many of the patterns that are seen in mammals, although Campbell and Ellis [5] stress that the exact functions of piscine granulocytes are not established, so direct comparisons with mammalian processes are somewhat speculative.

Polycythemia and anemia

Fish with a PCV of 45% or greater generally are considered to have a relative polycythemia resulting from dehydration, especially when in conjunction with an elevation in serum osmolality, total protein, sodium, or chloride. Polycythemia also can be observed, however, in sexually mature males, in freshwater fish exposed to hypoxia, in stressed fish resulting from release of catecholamines, during splenic contraction, and with erythrocyte swelling [6,23,24].

Anemias are well documented in fish. PCVs less than 20% in teleosts usually are associated with anemia. Diagnosing anemias in elasmobranchs can be more challenging as some species have a normal PCV of 20% or less (for example, sandbar shark [*Carcharhinus plumbeus*] and the Port Jackson shark [*Heterodontus portusjacksoni*]) [2,9]. The PCV of some sharks varies between blood collection sites and this possibility should be taken into account when diagnosing anemia [25]. There are three primary types of anemia: hemorrhagic (blood loss), hemolytic (erythrocyte destruction), and hypoplastic (poor erythropoiesis). The basic descriptive terminology used for anemias in other animals applies equally to fishes and may refer to cell size (microcytic, normocytic, or macrocytic), hemoglobin concentration (hypochromic or normochromic), cell loss (hemolytic or hemorrhagic), and hemopoietic status (regenerative or nonregenerative). Causes of nonregenerative anemias include inflammatory disease, nutritional disorders, toxins, and renal or splenic disease with disruption or destruction of hematopoietic tissues.

UNCORRECTED PROOF

ARTICLE IN PRESS

The specific hematologic presentation of a given anemia often provides indications as to the etiology of the disease.

Marked hemorrhage or hemolysis often results in microcytic anemia because regenerating immature erythrocytes make up the majority of cells in peripheral circulation and are smaller in size than mature erythrocytes. Marked polychromasia also may be noted. The presence of immature erythrocytes in circulation does not always signify a regenerative anemia; immature cells may be present in response to environmental stressors, such as hypoxia, toxins, or temperature change [18,26–28]. Hemorrhagic anemia in fish may be associated with trauma, cutaneous ulceration, parasitism (lampreys, leeches, and isopods) [5,29], nutritional deficiencies (vitamin K and B, inositol, and choline) [5,18], and viral or bacterial septicemia (Tables 1 and 2). When severe or chronic blood loss occurs, the net loss of iron may result in iron deficiency anemia. Hemolytic anemia in fish may be associated with hemolysin-producing bacteria (see Table 1), environmental toxins [30–32], viral infection [33], select nutritional deficiencies [34–36], and hemoparasites [3–5,37,38]. Marked regeneration often is noted with hemolytic anemia because the iron is not lost from the body and can be incorporated back into hemoglobin for hematopoiesis. Erythrocytes with pyknotic nuclei, erythroplastids, and erythrocyte fragmentation are associated with conditions that interfere with splenic removal of senescent erythrocytes from peripheral circulation [39]. Table 1 provides an overview of various causes and clinical presentations of anemia in teleosts.

Intrinsic and extrinsic induced variability

Stress factors in fish are variable and often relative as they are with other animals. Extrinsic factors, such as handling, transport, poor water quality, [Q6] and high population densities, initially may cause a significant stress response in most fish but with chronicity or acclimation the response may diminish. Stress response in fish is similar to that of higher vertebrates with a rapid release of catecholamines followed by the release of corticosteroids. A stress leukogram for most fish is manifested as a leukopenia with a lymphopenia and a relative granulocytosis. Hematologic changes associated with the stress response may persist for several days after the stressor is removed [40,41]. Juvenile teleosts have notably higher lymphocyte and total leukocyte counts compared with adults [15,23].

Noninfectious diseases also can manifest in the blood of fishes; these often are associated with husbandry practices and environment. Among husbandry-related diseases, a microcytic normochromic anemia can result from environmental stressors, such as increases in population density [42,43]. Higher lymphocyte and total leukocyte counts are found in fish from production systems with high densities, marginal water quality, and often elevated bacterial load [17]. Nitrite poisoning, also known as brown blood

UNCORRECTED PROOF

ARTICLE IN PRESS

Table 1
Some anemias and their etiologies in teleost fishes [Q17]

Etiology	Presentation	Citation
Hemorrhagic		
Bacterial		
Aeromonas sp	External/internal lesions, septicemia	Campbell and Ellis [5]
Pseudomonas sp	External/internal lesions, septicemia	Campbell and Ellis [5]
Yersinia sp	Reticulocytosis, septicemia	Tobback et al [54]
Ammonia toxicity	Microcytic normo or hypochromic	Groff and Zinkl [18]
Nutritional deficiency		
Vitamin K	Hypocoagulation, hypochromic	Groff and Zinkl [18]
Vitamin B	Hypocoagulation, hypochromic	Groff and Zinkl [18]
Inositol	Hypocoagulation, hypochromic	Groff and Zinkl [18]
Choline	Hypocoagulation, hypochromic	Groff and Zinkl [18]
Parasites		
Leech, lamprey, isopod	External lesions, pallor, macrocytic	Sinderman [68], Nair and Nair [29]
Iron deficiency	Macrocytic normo or hypochromic	Groff and Zinkl [18]
Viral (see Table 2)		
Hemolytic		
Bacterial		
Flavobacterium columnare	Fragmentation, macrocytic hypochromic	Rehulka and Minarik [56]
Aeromonas sp	Macrocytic, ± bacteremia, septicemia	Roberts and Ellis [50]
Pseudomonas sp	Macrocytic, ± bacteremia, septicemia	Roberts and Ellis [50]
Vibrio sp	Macrocytic, ± bacteremia, septicemia	Roberts and Ellis [50]
Toxins		
Nitrite	Methemoglobinemia, hypochromic	Avilez et al [30]
Mercury contamination	Macrocytic normo or hypochromic	Elahee and Bhagwant [32]
Chlorine	Heinz bodies, methemoglobinemia	Buckley [31]
Nutritional		
Folate deficiency	Pyknotic nuclei, erythroplastids, fragmentation	Plumb et al [35], Ferguson [34]
Vitamin E deficiency	Pyknotic nuclei, erythroplastids, fragmentation	Hibiya [46], Eiras 1983 [45] [Q18]
Yeast excess	Poikilocytosis, microcytic hypochromic	Sanchez-Muiz et al [47]
Hemoparasites		
Trypanoplasma	Microcytic hypochromic (cryptobiosis, sleeping sickness)	Woo [38], Rowley [49]
Trypanosoma	Microcytic hypochromic	Woo [37]
Piroplasmids	Intracytoplasmic	Campbell and Ellis [5]
Hypoxia	Macrocytic normo or hypochromic	Elahee and Bhagwant [32]
Viral (see Table 2)		
Hypoplastic		
Yersiniosis (chronic)	Septicemia, kidney/splenic necrosis	Tobback et al [54]
Toxins		
Ammonia	Cell fragility, impaired erythropoiesis	Groff and Zinkl [18]
Heavy metals	Impaired erythropoiesis, low hemoglobin	Groff and Zinkl [18], Noga [3]

UNCORRECTED PROOF

ARTICLE IN PRESS

Table 1 (*continued*)

Etiology	Presentation	Citation
Nutritional		
Starvation	Microcytic hypochromic, abnormal nuclei	Rios et al [48]
Vitamin B12 deficiency	Normocytic hypo or normochromic	Ferguson [34]
Parasites		
Trypanoplasma	Microcytic hypochromic, impaired production (Cryptobiosis, sleeping sickness)	Woo [38], Rowley [49]
Trypanosoma	Microcytic hypochromic, impaired production	Woo [37]
Myxozoans	Normocytic hypochromic, poikilocytosis	Hoffmann and Lommel [75]
Kidney or splenic disease	Erythropoietic tissue destruction/ displacement	Campbell and Ellis [5]

From Refs. [3,5,18,29–32,34,35,37,38,45–50,54,56,68,75].

disease or new tank syndrome, occurs because of incomplete nitrification of ammonium waste in closed or high-density culture situations and can result in cyanosis and hemolytic anemia [5,30]. Ammonia and heavy metal toxicoses can result in various forms of nonregenerative anemia [3,18]. Chronic exposure to cypermethrin, a synthetic pyrethroid insecticide, may cause enlargement of erythrocytes and abnormal erythrocyte morphology yielding a macrocytic anemia [44].

Nutritional disorders, such as folic acid and vitamin E deficiency or toxicosis from rancid oils and environmental pollutants, may contribute to formation of abnormal erythrocyte nuclei and erythroplastids [45,46]. Deficiencies in dietary vitamin K and B vitamins, inositol, and choline, may cause coagulation disorders resulting in hemorrhagic anemia [18]. Folate deficiency in channel catfish (*Ictalurus punctatus*) results in chronic hemolytic anemia [35,36]. Vitamin C, iron, or copper deficiency can cause

Table 2
Hematologic features of some viral diseases of teleost fishes

Disease	Host	Presentation	Citation
IHNV	Salmonids	Hemorrhagic, hypochromic, nonregenerative anemia; loss of acid-base equilibrium	Amend and Smith [60,61]
VHSV	Many species	Severe hemorrhagic and hemolytic anemia, relative monocytosis, lymphopenia, acute mortality	Egusa [64]
SVC	Cyprinids	Hemorrhagic hypochromic anemia, neutrophilia, monocytosis.	Egusa [64]
VEN	Marine species	Hemolytic anemia with prominent intraerythrocytic inclusions, typically a chronic progression	Hershberger et al [33]

From Refs. [33,60,61,64].

UNCORRECTED PROOF

ARTICLE IN PRESS

microcytic hypochromic anemia [18]. Rainbow trout fed diets containing certain peroxide-producing yeasts may develop microcytic hypochromic anemia with marked poikilocytosis [47]. Vitamin C and pyridoxine deficiencies may cause leukopenia, and biotin deficiency in cyprinids may result in leukocytosis [18]. Studies of a neotropical species, *Hoplias malabaricus*, revealed that food deprivation for extended periods may result in reversible leukopenia and thrombocytopenia [48].

Inflammatory processes

Granulocytosis often is associated with inflammation in teleost and cartilaginous fishes. Monocytes occur in low numbers in a differential white blood cell count but are actively phagocytic cells in piscine fishes [49]. A monocytosis is suggestive of an inflammatory response in teleost fishes. Neutrophilia often is associated with inflammatory processes, but neutrophils are not always phagocytic. An acute neutropenia may reflect extravasion of neutrophils at a focal site of significant insult. Some reports indicate that fish eosinophils are involved in inflammatory responses but have limited phagocytic capability [49,50].

Cell-mediated abnormalities

Lymphocytosis may indicate a leukemic condition and typically are accompanied by cellular signs of degeneration, immaturity, or malignancy. Lymphocytes play an important role in humoral and cell-mediated immunity in fish [51,52]. Lymphocytosis may be suggestive of immunogenic stimulation, whereas lymphopenia may be suggestive of immunosuppressive conditions.

Infection-induced abnormalities

Bacterial disease

Gram-negative bacteria, such as *Aeromonas* spp and *Pseudomonas* spp, are common causes of septicemia and hemorrhagic anemia in freshwater fish [18]. *Aeromonas* spp, *Pseudomonas* spp, and *Vibrio anguillarum* produce hemolysins and are the most common causes of hemolytic anemia in fish [18,50]. Yersiniosis of marine fish causes hemorrhagic septicemia characterized by anemia, leukocytosis, and reticulocytosis [53,54]. A severe hemorrhagic anemia caused by cold-water vibriosis (Hitra disease) was documented in juvenile Atlantic salmon (*Salmo salar*) [55]. Brook trout (*Salvelinus fontinalis*) affected by columnaris disease (*Flavobacterium columnare*) developed macrocytic hypochromic anemia with evidence of fragmented erythrocytes noted on blood smears [56]. Fig. 3 shows a gram-positive septicemia caused by *Streptococcus iniae* in a yellow tang (*Zebrasoma flavescens*). In sharks, increases in granulocytes and decreases in lymphocytes can be associated with bacterial septicemia. Leukopenia with lymphopenia or a relative neutrophilia is [Q7]

UNCORRECTED PROOF

ARTICLE IN PRESS

print & web 4C/FPO

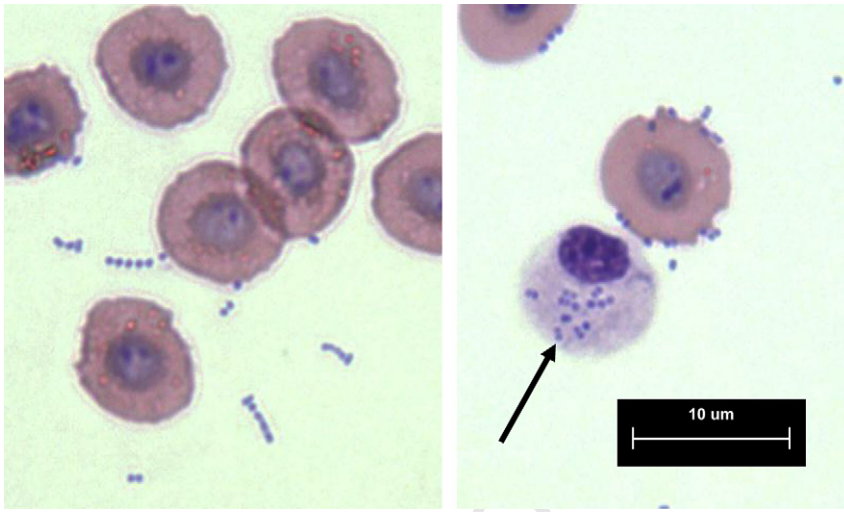

Fig. 3. Bacterial disease in a blood smear: gram-positive septicemia caused by *Streptococcus iniae*, in a yellow tang (*Zebrasoma flavescens*). Cocci are present free in the plasma and intracellularly within a neutrophil (*arrow*).

UNCORRECTED

indicative of a stress response or sepsis [4,5]. Proliferative kidney disease (PKD)-affected fish are believed particularly sensitive to bacterial challenge because of the depression of granulocyte activity [57].

Viral disease

Of the myriad viral infections known from fishes, several are expressed prominently in blood, most often through the presence of intraerythrocytic inclusions or profound hemorrhagic or hemolytic anemia. Erythrocytic necrosis virus (VEN) causes hemolytic anemia and is associated with intracytoplasmic inclusions and nuclear changes in the erythrocyte of marine fish [33,58]. Erythrocytic inclusion body syndrome virus also results in intracytoplasmic inclusions but is distinct from VEN. It is associated with transient anemia in freshwater Pacific salmon in the United States but has had no adverse effects on other infected species [59]. Infectious hematopoietic necrosis virus (IHNV) infects a range of salmonid and other fish species, wherein it obliterates the lymphoid tissues of the spleen and head kidney [60,61]. Viral hemorrhagic septicemia (VHSV) has become a prominent emerging disease in the North American fisheries scene since an apparent epizootic started in the Great Lakes region in 2005 [62,63]. Spring viremia of carp (SVC) is a disease restricted to freshwater cyprinid fishes and like VHSV, it causes hemorrhagic anemia [64]. Channel catfish virus (*Herpesvirus ictaluri*) causes acute hemorrhage at the bases of the fins and in liver, kidney, and the gastrointestinal system [65,66]. Table 2 provides an overview of the clinical presentations associated with the viral diseases discussed. [Q8]

ARTICLE IN PRESS

Parasitic disease

Several parasites, mostly protistan, manifest in the blood of teleosts; these may be intraerythrocytic or occur in the plasma. *Trypanosoma* probably is the best-known extraerythrocytic protist in fish (Fig. 4). Fish trypanosomes essentially have the same appearance as those that cause sleeping sickness in humans (*T brucei*) and trypanosomiasis in domestic animals, although they usually are larger (example, *T mukasai* large form $>$ 80 μm) [67] and occur at much heavier intensities than do mammalian kinetoplastids. Despite their higher parasitemia, they are infrequently pathogenic but are capable of causing fatal anemias [37]. Fish trypanoplasms are very similar in morphology to trypanosomes and are extraerythrocytic protists. *Cryptobia* (*Trypanoplasma*) *salmositica* [38] causes cryptobiosis in salmonids and may result in severe anemia because of destruction of hematopoietic tissue. *Trypanoplasma borreli* causes sleeping sickness in cyprinids with systemic illness and progressive anemia [49]. Species of trypanosomes and trypanoplasms with known life cycles are transmitted by leeches rather than arthropods.

The intraerythrocytic hemogregarines probably are the most common hemoparasites of teleosts [68,69]. Among elasmobranchs, they have been found in spiny dogfish *Squalus acanthias* [70], epaulette sharks (*Hemiscyllium ocellatum*) [71], and cat sharks (Fig. 5). Possible vectors are leeches and isopods. These usually occur as small to larger cellular inclusions in the cytoplasm of erythrocytes (see Diniz and colleagues for example [72]),

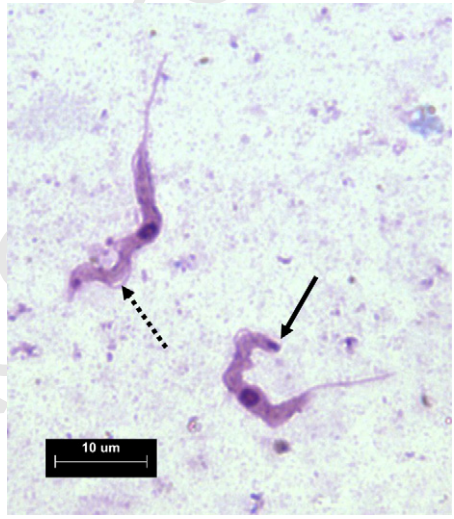

Fig. 4. Protistan disease in a blood smear: trypanosmiasis caused by an undescribed *Trypanosoma* species, in straight-backed freshwater catfish, *Neosilurus hyrtilii* from Australia. These are typical trypanosomes in possessing a recurrent flagellum that originates from a darkly staining kinetoplastid organelle (*solid arrow*) and attached to the cell by an undulating membrane (*dashed arrow*).

print & web 4C/FPO

UNCORRECTED PROOF

ARTICLE IN PRESS

print & web 4C/FPO

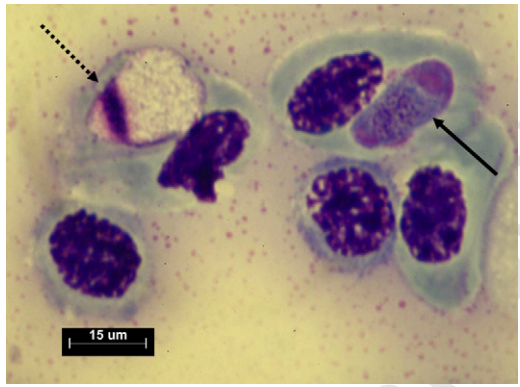

Fig. 5. Protistan disease in a blood smear: two hemogregarine morphotypes in the blood of the catshark, *Holohalaelurus punctatus*. One type (*solid arrow*) shows a fairly typical hemogregarine presentation, displacing the nucleus and with a distinct nucleus, whereas the other (*dashed arrow*) shows an unusual frothy appearance with the nucleus displaced to one pole. *(Courtesy of* Dr. Nico Smit, Department of Zoology, University of Johannesburg, South Africa.)

with or without a parasitophorous vacuole (a membrane-bound space surrounding an intracytoplasmic parasite and preventing direct contact with the cytoplasm) and with a distinct basophilic nucleus. They may appear similar to the large hemogregarines of birds and reptiles, such as *Haemoproteus*, occupying more than half of the cytoplasmic space and curving around the erythrocyte nucleus, or they may resemble the smaller, more basophilic piroplasms of mammals, such as *Babesia* spp, occurring singly or as pairs or tetrads, depending on the particular genus of parasites (see van der Straaten and colleagues for example [69]). Intraerythrocytic protist parasites of fishes (and amphibians) have been comprehensively reviewed by Davies and Johnston [73].

Many metazoan parasites cause hematologic changes, most commonly anemia, due to the consumption of host blood as part of the normal feeding biology of the parasite. They also may cause anemia by disruption of hematopoeisis. Elevated eosinophil counts are suggestive of an inflammatory response associated with antigenic stimulation or parasitic infections, such as metazoans. Leeches and lampreys are blood-sucking parasites that are large compared with most parasites and, therefore, can cause profound hemorrhagic anemia in fish. A study with captive blackeye thicklip (Labridae) showed that parasitic isopods (*Gnathia* sp) can significantly reduce hematocrit [74] as a result of the ''tick-like'' biology of female gnathiids, wherein they take periodic large blood meals before leaving the host to mate and molt in the substrate. Rainbow trout (*Salmo gairdneri*) affected by PKD, caused by the myxozoan parasite *Tetracapsuloides bryosalmonae*, develop a chronic normocytic hypochromic anemia with distinct poikilocytosis [75].

UNCORRECTED PROOF

ARTICLE IN PRESS

Thrombocytes and hemostasis

Thrombocytes play a large role in mediating the clotting response. They typically are small cells, ovoid, oblong, or spindle shaped (often all three in any given smear), with clear cytoplasm and a condensed basophilic nucleus. Some elasmobranch species have a second population of thrombocytes; in addition to the cell identical to that described for teleosts, there are thrombocytes with abundant FEGs in the cytoplasm. The clinical significance of these cells is not yet understood. Fish seem to rely primarily on extrinsic pathways of coagulation. Clot formation usually occurs within 5 minutes in teleosts whereas it may take greater than 20 minutes for some elasmobranchs to clot. Thrombocytopenia could have devastating affects on fish as not only are they responsible for blood clotting but also they are responsible for controlling fluid loss from surface wounds in fish. High levels of [Q9] glucocorticoids decrease the number of thrombocytes and increase clotting times. Prolonged clotting times also is attributed to vitamin K deficiency [5].

Summary

Hematology of fishes lags behind that of other classes of vertebrates, but analysis of blood still can be informative about disease processes in teleosts and elasmobranchs. Although robust interpretation of fish hemograms often is hampered by a lack of reference values, this knowledge deficit represents an opportunity for expansion of clinical pathology studies among fishes. This article offers a summary of some of the more common hematologic abnormalities documented in fish and insight to some of the more obscure causes of hematologic variations and abnormalities that warrant further investigation and documentation. Practitioners are encouraged to obtain samples whenever possible as they can benefit individual animals and contribute to establishment of reference data.

References

[1] Bolasina SN. Cortisol and hematological response in Brazilian codling, *Urophycis brasilienisis* (Pisces, Phycidae) subjected to anesthetic treatment. Aquac Int 2006;14:569–75.
[2] Campbell TW. Tropical fish medicine. Fish cytology and hematology. Vet Clin North Am Small Anim Pract 1988;18:347–64.
[3] Noga EJ. Fish disease: diagnosis and treatment. Ames (IA): Iowa State Press; 2000.
[4] Campbell TW. Hematology of fish. In: Troy DB, editor. Veterinary hematology and clinical chemistry. Baltimore: Lippincott Williams & Wilkins; 2004. p. 277–89.
[5] Campbell T, Ellis C. Avian and exotic animal hematology and cytology. New York: Wiley-Blackwell; 2007.
[6] Fange R. Fish blood cells. In: Hoar WS, Randall DJ, Farrell AP, editors. Fish physiology, vol. 12B. San Diego (CA): Academic Press Inc; 1992. p. 1–54.
[7] Glomski CA, Tamburlin J, Chainani M. They phylogenetic odyssey of the erythrocyte. III. Fish, the lower vertebrate experience. Histol Histopathol 1992;7:501–28.

UNCORRECTED PROOF

ARTICLE IN PRESS

[8] Walsh CJ, Luer CA. Elasmobranch hematology: identification of cell types and practical applications. In: Smith M, Warmolts D, Thoney D, et al, editors. The elasmobranch husbandry manaual: captive care of sharks, rays and their relatives. Columbus (OH): Ohio Biological Survey, Inc; 2004. p. 307–23.
[9] Arnold JE. Hematology of the sandbar shark, *Carcharhinus plumbeus*: standardization of complete blood count techniques for elasmobranchs. Vet Clin Pathol 2005;34(2): 115–23.
[10] Lane HC. Progressive changes in hematology and tissue water of sexually mature trout, *Salmo gairdneri* Richardson during the autumn and winter. 1979;15:425–36. [Q10]
[11] Hille SA. A literature review of the blood chemistry of rainbow trout, *Salmo gairdneri* Richardson. J Fish Biol 1982;20:535–69.
[12] Ram-Bhaskar B, Srinivasa-Rao K. Influence of environmental variables on hematology, and compendium of normal hematological ranges of milkfish, *Chanos chanos* (Forskal) in brackish culture. Aquaculture 1989;83:123–36.
[13] Hrubec TC, Robertson JL, Smith SA. Effects of temperature on hematological and serum biochemical profiles of hybrid striped bass (Morone chrysops x Morone saxatilis). Am J Vet Res 1997;58(2):126–30.
[14] Hrubec TC, Robertson JL, Smith SA. Effects of ammonia and nitrate concentration on hematologic and serum biochemical profiles of hybrid striped bass (Morone chrysops × Morone saxatilis). Am J Vet Res 1997;58:131–5.
[15] Hrubec TC, Smith SA, Robertson JL. Age-related changes in hematology and plasma chemistry values of hybrid striped bass (Morone chrysops × Morone saxatilis). Vet Clin Pathol 2001;30:8–15.
[16] Valenzuela AE, Silva VM, Klempau AE. Some changes in the hematological parameters of rainbow trout *(Oncorhynchus mykiss)* exposed to three artificial photoperiod regimes. Fish Physiol Biochem 2007;33:35–48.
[17] Hrubec TC, Smith SA. Hematology of fish. In: Feldman BF, Zinkl JG, Jain NC, editors. Schalm's veterinary hematology. 5th edition. Philadelphia: Lippincott Williams & Wilkins; 2000. p. 1120–5.
[18] Groff JM, Zinkl JG. Hematology and clinical chemistry of cyprinid fish. Vet Clin North Am Exot Anim Pract 1999;2(3):741–76.
[19] Zinkle JG, Cox WT, Kono CS. Morphology and cytochemistry in leucocytes and thrombocytes of six species of fish. Comp Haemat Inter 1991;1:187–95. [Q11]
[20] Hine PM, Wain JM. Composition and ultrastructure of elasmobranch granulocytes. I. Dogfishes (Squaliformes). J Fish Biol 1987;30:547–56.
[21] Hine PM, Wain JM. Composition and ultrastructure of elasmobranch granulocytes. II. Rays (Rajiformes). J Fish Biol 1987;30:557–65.
[22] Hine PM, Wain JM. Composition and ultrastructure of elasmobranch granulocytes. III. Sharks (Lamniformes). J Fish Biol 1987;30:567–76.
[23] Blaxhall PC. The hematological assessment of the health of freshwater fish: a review of selected literature. J Fish Biol 1972;4:593–604.
[24] McDonald DG, Milligan CL. Chemical properties of the blood. In: Hoar WS, Randall DJ, Farrell AP, editors. Fish physiology, vol. 12B. San Diego (CA): Academic Press Inc; 1992. p. 55–133.
[25] Mylniczenko ND, Curtis EW, Wilborn RE, et al. Differences in hematocrit of blood samples obtained from two venipuncture sites in sharks. Am J Vet Res 2006;67(11):1861–4.
[26] Houston AH, Murad A. Hematological characterization of goldfish (*Carassius auratus* L) by image analysis. Effects of thermal acclimation and heat shock. Can J Zool 1991;69: 2041–7.
[27] Houston AH, Murad A. Erythrodynamics in goldfish (*Carassius auratus* L). Temperature effects. Physiol Zool 1992;65:55–76.
[28] Houston AH, Schrapp MP. Thermoacclimatory hematological response: have we been using appropriate conditions and assessment methods? Can J Zool 1994;72:1238–42.

UNCORRECTED PROOF

ARTICLE IN PRESS

669 [29] Nair GA, Nair NB. Effect of infestation with the isopod, *Alitropus typus* M. Edwards
670 (Crustacea: Flabellifera: Aegidae) on the haematological parameters of the host fish, *Channa*
671 *striatus* (Bloch). Aquaculture 1983;30:11–9.
672 [30] Avilez IM, Altran AE, Aguiar LH, et al. Hematological responses of the Neotropical teleost
673 matrinxã (*Brycon cephalus*) to environmental nitrite. Comp Biochem Physiol C Toxicol
674 Pharmacol 2004;139:135–9.
675 [31] Buckley JA. Heinz body hemolytic anemia in coho salmon, *Oncorhynchus kisutch*, exposed
676 to chlorinated waste water. J Fish Res Bd Canada 1976;34:215–24.
677 [32] Elahee KB, Bhagwant S. Hematological and gill histopathological parameters of three
678 tropical fish species from a polluted lagoon on the west coast of Mauritius. Ecotoxicol
679 Environ Saf 2007;68(3):361–71.
680 [33] Hershberger P, Hart A, Gregg J, et al. Dynamics of viral hemorrhagic septicaemia, viral
681 erythrocytic necrosis and ichthyophoniasis in confined juvenile Pacific herring *Clupea*
682 *pallasii* 2006;70:201–8.
683 [34] Ferguson HW. Spleen, blood, lymph, thymus and reticuloendotheial system. In: Systemic
684 pathology of fish. Ames (IA): Iowa State University Press; 1989. [Q12] [Q13]
685 [35] Plumb JA, Liu PR, Butterworth CE. Folate-degrading bacteria in channel catfish feeds.
686 J Appl Aquacult 1991;1:33–43.
687 [36] Duncan PL, Lovell RL, Butterworth CE, et al. Dietary folate requirement determined for
688 channel catfish, Ictalurus punctatus. J Nutr 1993;1888–97. [Q14]
689 [37] Woo PTK. *Cryptobia* and cryptobiosis in fishes. Adv Parasitol 1987;26:199–237.
690 [38] Woo PTK. Review: *Cryptobia (Trypanoplasma) salmositica* and salmonid cryptobiosis.
691 J Fish Dis 2003;26(11–12):627–46.
692 [39] Ellis AE. Bizarre forms of erythrocytes in a specimen of plaice, Pleuronectes platessa L.
693 J Fish Dis 1984;7:411–4.
694 [40] Houston AH. Blood and circulation. In: Schreck C, Moyle B, editors. Methods in fish
695 biology. Bethesda (MD): American Fisheries Society; 1990.
696 [41] Wedemeyer GA, Barton BA, McLeay DJ. Stress and acclimation. In: Schreck C,
697 Moyle P, editors. Methods in fish biology. Bethesda (MD): American Fisheries Soci-
698 ety; 1990.
699 [42] Burton CB, Murray SA. Effects of density on goldfish blood. 1. Hematology Comp Biochem
700 Physiol A 1979;62:555–8.
701 [43] Murray SA, Burton CB. Effects of density on goldfish blood. 2. Cell morphology. Comp
702 Biochem Physiol A 1979;62:559–62.
703 [44] Saxena KK, Seth N. Toxic effects of cypermethrin on certain hematological aspects of fresh
704 water fish *Channa punctatus*. Bull Environ Contam Toxicol 2002;69:364–9.
705 [45] Eiras JC. Erythrocyte degeneration in the European eel, Anguilla anguilla. Bull Eur Assoc
706 Fish Pathol 1985;3:8–10.
707 [46] Hibiya T, editor. An atlas of fish histology: normal and pathological features. Tokyo:
708 Kodansha; 1985.
709 [47] Sanchez-Muiz FJ, de la Higuera M, Varela G. Alterations of erythrocytes of the rainbow
710 trout *Salmo gairdneri* by the use of *Hansenula anomola* yeast as sole protein source. Comp
711 Biochem Physiol A 1982;72:693–6.
712 [48] Rios FS, Oba ET, Fernandes MN, et al. Erythrocyte senescence and hematological changes
713 induced by startvation in the neotropical fish traíra, *Hoplias malabaricus* (Characiformes,
Erythrinidae). Comp Biochem Physiol A 2005;140(3):281–7.
[49] Rowley AF. Fish. In: Rowley AF, Ratcliffe N, editors. Vertebrate blood cells. Cambridge:
Cambridge University; 1988.
[50] Roberts RJ, Ellis AE. The anatomy and physiology of teleosts. In: Roberts R, editor. Fish
pathology. Philadelphia: WB Saunders; 2001.
[51] Clem LW, Miller NW, Bly JE. Evolution of lymphocyte subpopulations, their interactions
and temperature sensitivities. In: Cohen N, Warr G, editors. The phylogeny of immune
functions. Boca Raton (FL): CRC Press; 1991.

UNCORRECTED PROOF

ARTICLE IN PRESS

[52] Evans DL, Jaso-Friedmann L. Nonspecific cyto-toxic cells as effectors of immunity in fish. Annu Rev Fish Dis 1992;2:109–21.
[53] Stokes EE, Firkin BG. Studies of the peripheral blood of the Port Jackson shark (*Heterodontus portusjacksoni*) with particular reference to the thrombocyte. Br J Hematol 1971;20: 427–35.
[54] Tobback E, Decostere A, Hermans K, et al. Review: Yersinia ruckeri infections in salmonid fish. J Fish Dis 2007;30:257–68.
[55] Waagbo R, Sandness K, Espelid S, et al. Hematological and biochemical analyses of Atlantic salmon *Salmo salar* L., suffering from coldwater vibriosis ('Hitra disease'). J Fish Dis 1988; 11:417–23.
[56] Rehulka J, Minarik B. Blood parameters in brook trout *Salvelinus fontinalis* (Mitchill, 1815), affected by columnaris disease. Aquac Res 2007;38(11):1182–97.
[57] Chilmonczyk S, Monge D, deKinkelin P. Proliferative kidney disease: cellular aspects of the rainbow trout, *Oncorhynchus mykiss* (Walbaum), response to parasitic infection. J Fish Dis 2002;25(4):217–26.
[58] Wolf K. Viral erythrocytic necrosis. In: Wolf K, editor. Fish viruses and fish viral diseases. Ithica, NY: Cornell University Press; 1988. p. 389–98.
[59] Rodger HD. Erythrocytic inclusion body syndrome virus in wild Atlantic salmon, *Salmo salar* L. J Fish Dis 2007;30:411–8.
[60] Amend DF, Smith L. Pathophysiology of infectious hematopoeitic necrosis virus disease in rainbow trout (*Salmo gairdneri*): early changes in blood and aspects of immune response after injection with IHN virus. J Fish Res Board Can 1974;31:1371–8.
[61] Amend DF, Smith L. Pathophysiology of infectious hematopoeitic necrosis virus disease in rainbow trout (*Salmo gairdneri*): hematological and blood chemical changes in moribund fish. Infect Immunity 1975;11:171–9.
[62] Řehulka J. Hematological analyses in rainbow trout *Oncorhynchus mykiss* affected by viral hemorrhagic septicaemia (VHS). Dis Aquat Org 2003;56:185–93.
[63] Lumsden JS, Morrison B, Yason C, et al. Mortality event in freshwater drum *Aplodinotus grunniens* from Lake Ontario, Canada, associated with viral hemorrhagic septicemia virus, Type IV. Dis Aquat Org 2007;76:99–111.
[64] Egusa S. Infectious diseases of fish. Tokyo: Koseisha Koseikaku Publishing; 1992.
[65] Gray WL, Williams RJ, Grin BR. Detection of channel catfish virus DNA in acutely infected channel catfish, *Ictalurus punctatus* using the polymerase chain reaction. J Fish Dis 1999;22: 111–6.
[66] Gray WL, Williams RJ, Jordan RL, et al. Detection of channel catfish virus DNA in latently infected catfish. J Gen Virol 1999;80:1817–22.
[67] Smit NJ, Van As JG, Davies AJ. Fish trypanosomes from the Okavango Delta, Botswana. Folia Parasitol 2004;51:299–303.
[68] Sindermann CJ. Principal diseases of marine fish and shellfish. San Diego (CA): Academic Press; 1990.
[69] van der Straaten N, Jacobson A, Halos D, et al. Prevalence and spatial distribution of intra-erythrocytic parasite(s) in Puget Sound rockfish (Sebastes emphaeus) from the San Juan Archipelago, Washington (USA). J Parasitol 2005;980–2.
[70] Clewley A, Kocan RM, Kocan AA. An intraerythrocytic parasite from the spiny dogfish, *Squalus acanthias* L., from the Pacific Northwest. J Fish Dis 2002;25(11):693–6.
[71] McKiernan JP, Grutter AS, Davies AJ. Reproductive and feeding ecology of parasitic gnathiid isopods of epaulette sharks (*Hemiscyllium ocellatum*) with consideration of their role in the transmission of a hemogregarine. Journal of International Parasitology 2005; 35:19–27. [Q15]
[72] Diniz JA, Silva EO, deSouza W, et al. Some observations on the fine structure of trophozoites of the hemogregarines *Cyrilia lignieresi* (Adelina: Hemogregarinidae) in erythrocytes of the fish *Synbranchus marmoratus* (Synbranchidae). Parasitol Res 2002; 88:593–7.

UNCORRECTED PROOF

ARTICLE IN PRESS

759 [73] Davies AJ, Johnston MRL. The biology of some intraerythrocytic parasites of fishes
760 amphibia and reptiles. Adv Parasitol 2000;45:2–109. [Q16]
761 [74] Jones CM, Grutter AS. Parasitic isopods (*Gnathia* sp) reduce hematocrit in cap-
762 tive blackeye thicklip (Labridae) on the Great Barrier Reef. J Fish Biol 2005;
763 66:860–4.
764 [75] Hoffmann R, Lommel R. Hematological studies in proliferative kidney disease of rainbow
765 trout (*Salmo gairdneri* Richardson). J Fish Dis 1984;7:323–6.

UNCORRECTED PROOF